



# Steiner Ranch Orthodontics

## *Beautiful Smiles by Design*

*Adult Orthodontics, ages 18 to 78*

*Comprehensive, Limited and Adjunctive Cases*

*Working with local dentists & specialists to maximize your dental experience*



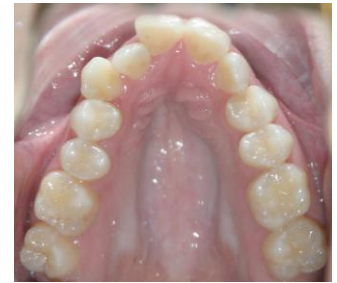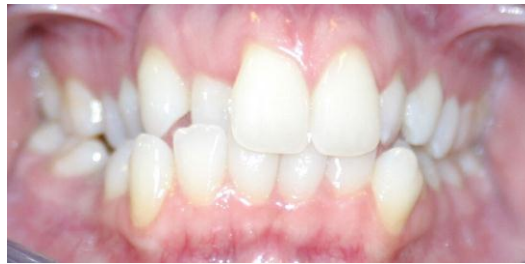Member  
American Association of  
Orthodontists®



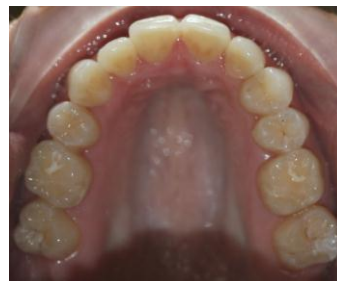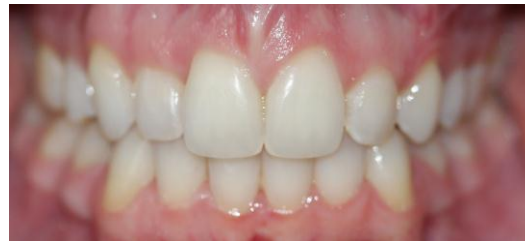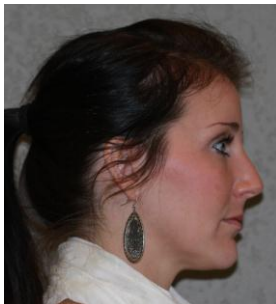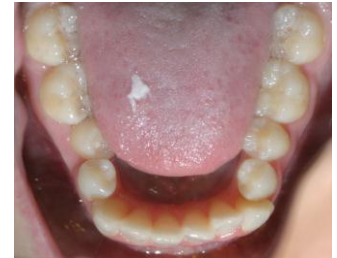[www.BracesAustin.com](http://www.BracesAustin.com)

 DIPLOMATE  
AMERICAN BOARD  
OF ORTHODONTICS

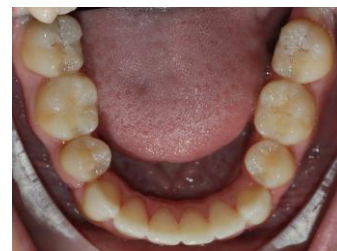# Severe Crowding, Mutilated Dentition



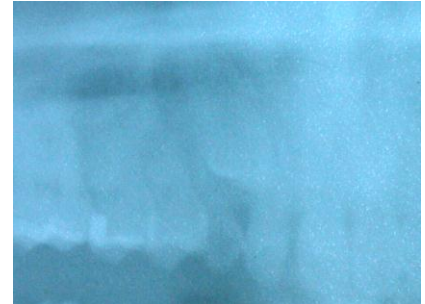
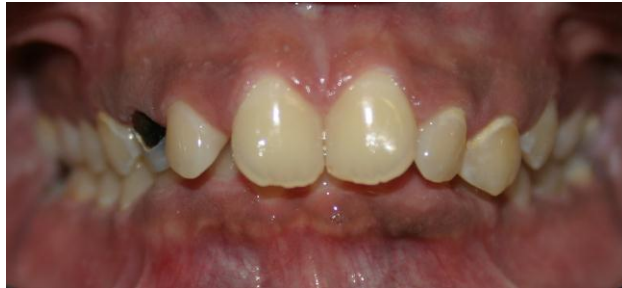**23y 2mo** Initial photos revealing a severe posterior crossbite with anterior crossbite and 3mm midline discrepancy. The upper left cuspid was impacted horizontal and too high to save; we removed the impacted cuspid and three 1<sup>st</sup> bicuspid to balance the missing cuspid.



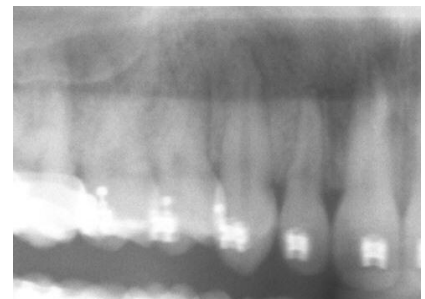
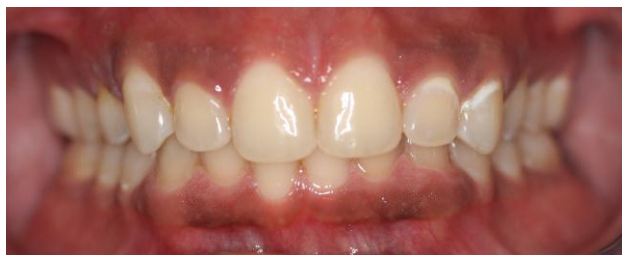**26y 0mo** Following braces, the crossbite was first corrected using a bonded RPE; once extractions were performed, the teeth were aligned and midlines corrected using extraction spaces. Note the new maxillary arch forms along with the completely closed extraction spaces. Overjet and Overbite were corrected to ideal.



# Adult Impacted Cuspids, Deepbite into Palate with crowding; Non-extraction Braces



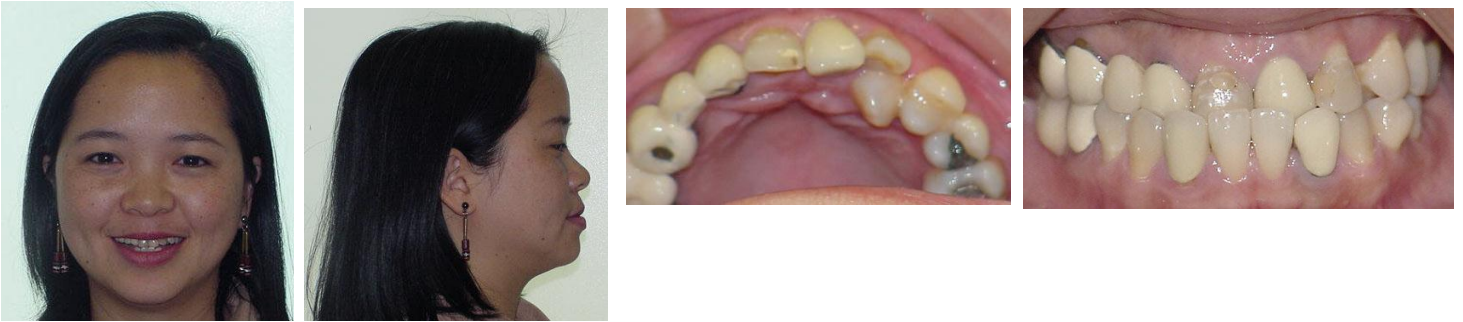
**Initial Photos taken at age 24y 8mo showing a severe deepbite with a retained and heavily decayed upper right primary canine; the X-Ray reveals the permanent canine remaining impacted high up under the baby tooth. Ironically he had the same on the lower right. Consider also the rotation of the front teeth and the narrow maxillary arch.**



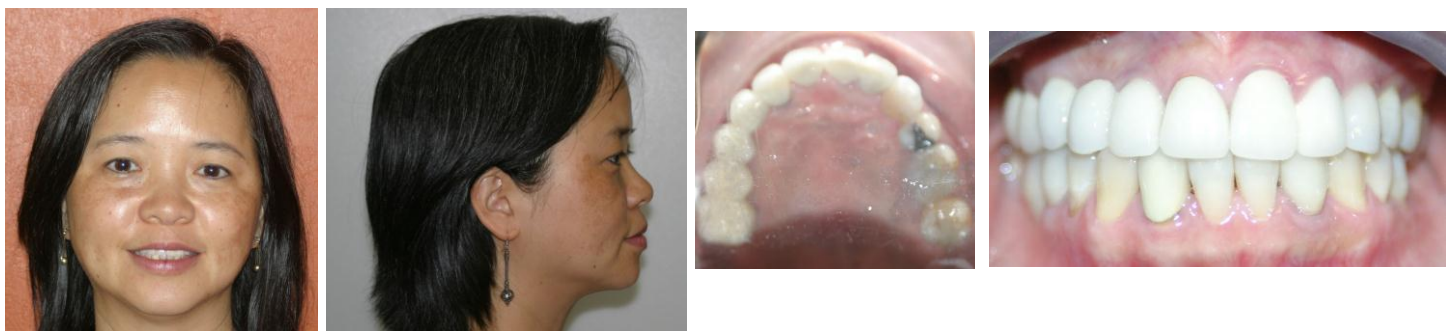**Photos taken at 27y 2mo, a full 4 months following removal of braces. Note the baby canines were removed and the impacted teeth were exposed and pulled out of the bone and into position with braces; all the while the bite was opened and all rotations corrected to provide an ideal overjet/overbite and Class I occlusion with ideal function. Of course he looks good as well!**



## Adult Class III Underbite with Extensive Restorative



**This adult patient presents with a severe Class III underbite with eruption of her upper left cuspid into her palate. There were multiple failed crowns and fillings.**



**Following full braces, the underbite was corrected and teeth set up in ideal overjet and overbite for new crowns. Note also the change in profile with a less prominent lower lip following treatment.**



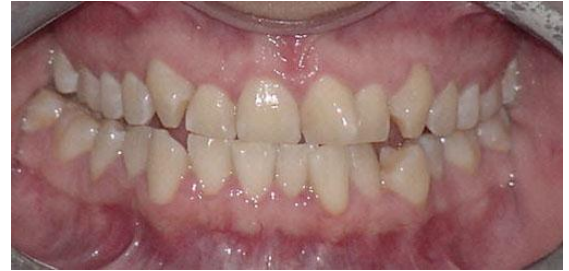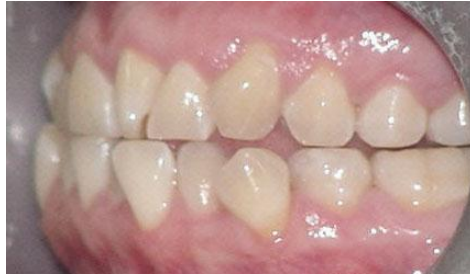Member  
American Association of  
Orthodontists



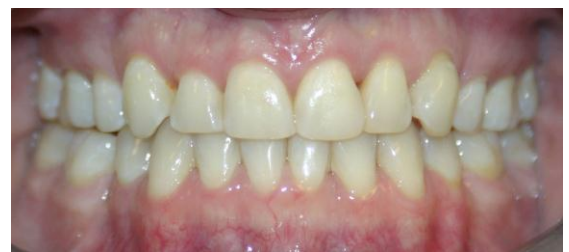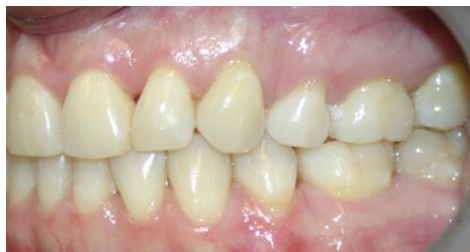[www.BracesAustin.com](http://www.BracesAustin.com)

 **DIPLOMATE  
AMERICAN BOARD  
OF ORTHODONTICS**

## Adult Severe Crowding with Crossbite, 4 Bicuspid Extraction

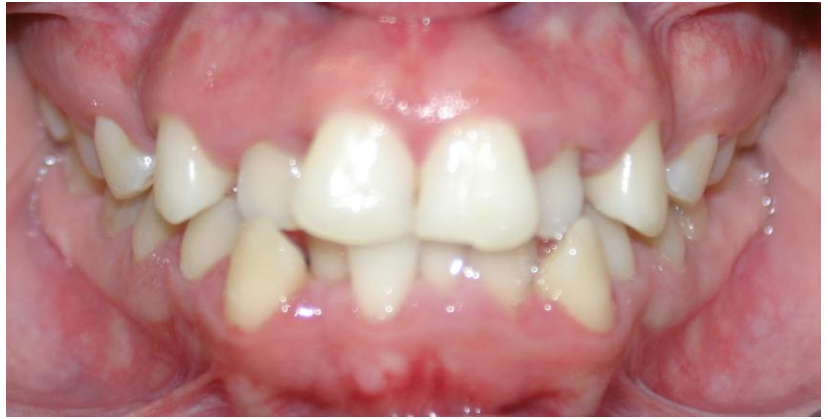

**This adult presented with severe crowding, anterior and posterior crossbite and an ever-shifting bite with severe wear. The patient reported never having a repeatable bite or good fit between upper and lower teeth. Note her midlines are off by an entire tooth.**

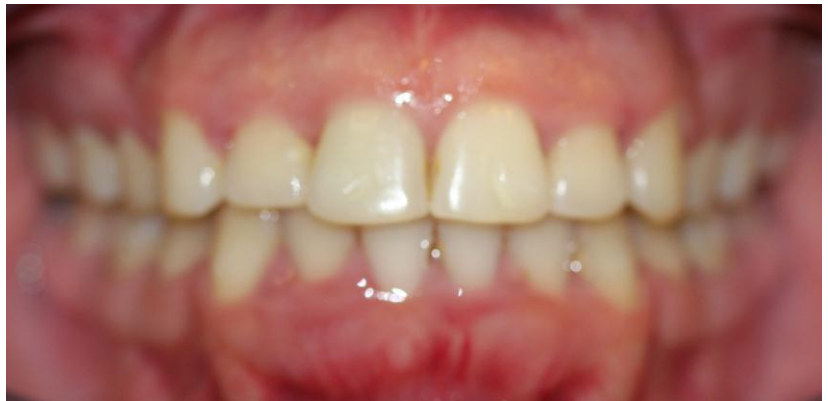

**Pictures taken 2 years after braces were removed; Full braces were on for 28 months during which time all 1<sup>st</sup> bicuspid were removed. All teeth have been aligned, the upper and lower arches coordinated to fit with midlines coincident. Of course all space from extraction of bicuspid has been closed.**

## Adult Severe Crowding with Missing upper Bicuspid



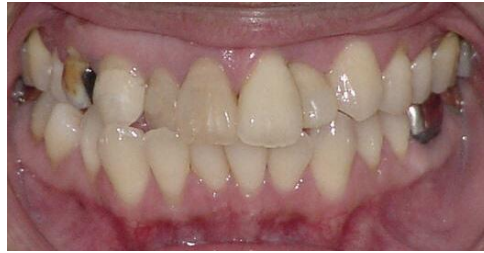**This 20 year old patient presented with severe crowding and missing upper bicuspid removed as a child (in a failed attempt to avoid crowding).**



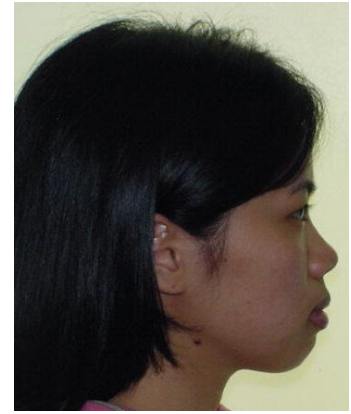**12 months after braces were removed (braces which included removal of two lower bicuspid), alignment was completed and occlusion restored to ideal overjet and overbite. Removable retainers were used 6 months full time and 6mo nights only; all spaces remain closed and alignment remains excellent.**



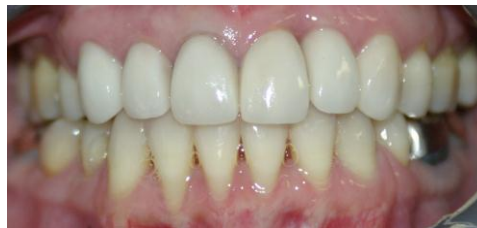## Adult Severe Crowding with Protrusive lips and Multiple Old/Fractured Restorations



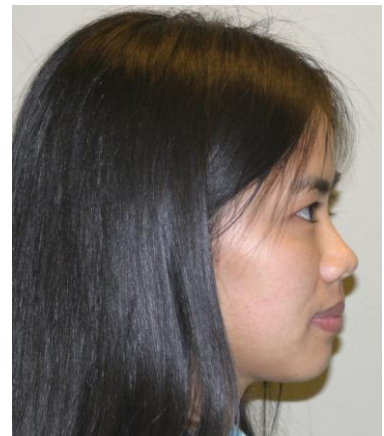This 30y 4mo patient presented with severe crowding, multiple old restorations in poor condition and an anterior crossbite. Her lips were also protrusive.



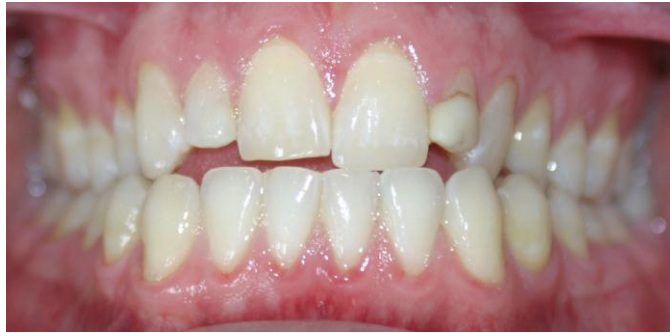Treatment was performed with full braces to realign teeth and set her lower teeth further back behind her upper teeth to restore proper overjet and overbite. We also wanted to reduce the facial protrusion visible in her profile picture (above right). Four bicuspids were removed (the upper right bicuspid removed was already hopeless due to fracture and recurrent decay).



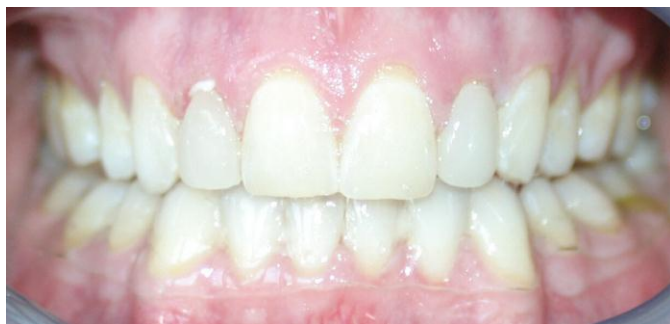Now at age 33y, 0mo the patient can be seen following braces and after restoration of her upper incisors. Overjet and overbite have been corrected to ideal and the facial profile corrected allowing us to reduce lip protrusion.



## **Adult Class III with Small Lateral Incisors (Full Braces with 4 Bicuspid Extractions & Veneers)**



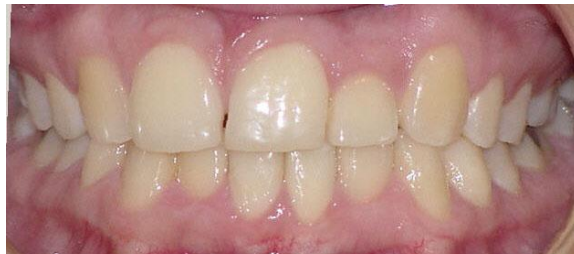**This adult patient presented with a Class III underbite and small upper lateral incisors. Treatment was planned with removal of all 1<sup>st</sup> bicuspid.**



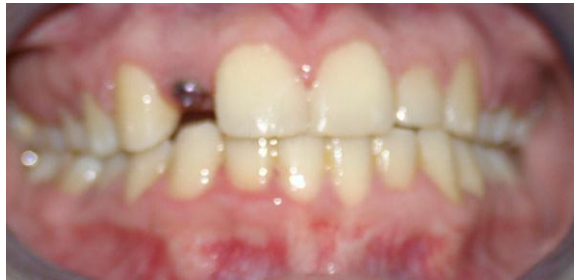**Now following braces you can see the lower teeth were brought back behind the patient's upper teeth and the arches were leveled to the ideal overjet and overbite; space was opened around the lateral incisors and veneers were placed.**



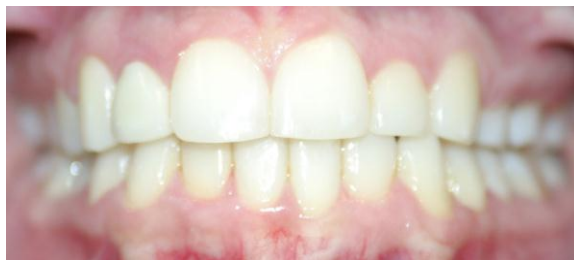## Adult Missing Lateral Incisor, Braces to Open Space for Implant



**This adult patient was born missing her upper left lateral incisor; previous braces were used as an adolescent to close space around the missing tooth.**

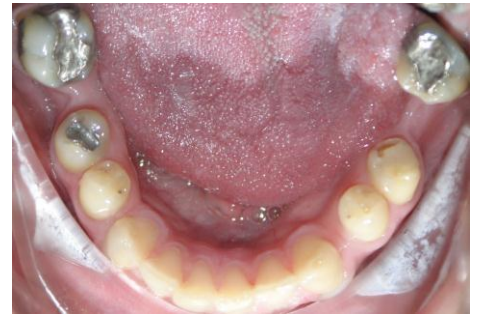
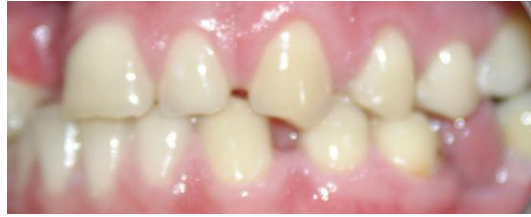
**Braces were used to re-open space over the missing tooth location and the midline was corrected by removal of a single bicuspid on her opposite side. Here the implant has been placed.**

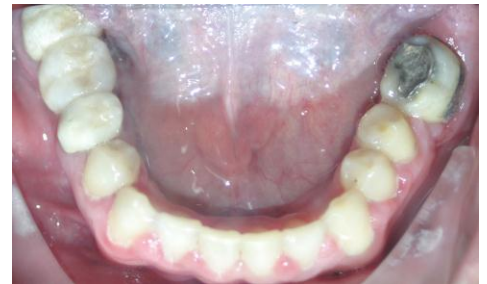
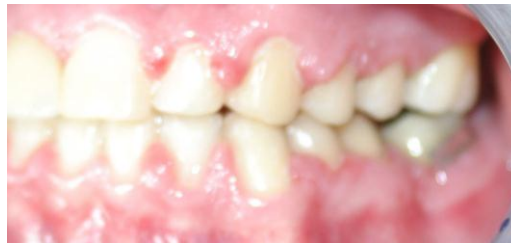
**After placement of the implant and correction of the midlines; note the upper teeth have been set directly in the middle of the patient's face and the implant matches the size of the opposite lateral incisor.**

## Adult Incisor Implant while closing missing space from missing lower left molar



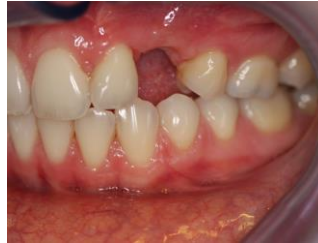This Patient presented with a missing upper right central incisor and missing lower right/left 1<sup>st</sup> molars; all had been out for many years allowing drift of adjacent teeth.



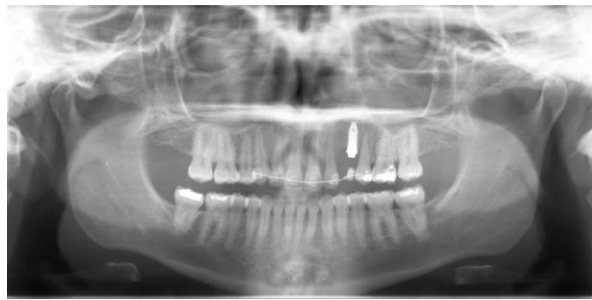Treatment focused on setting up incisors for an implant to replace the missing central. Space on the lower right from the missing molar was closed by pushing bicuspid forward and placement of a porcelain bridge (we needed contact with upper molars). Since upper left 2<sup>nd</sup> and 3<sup>rd</sup> molars were missing, we pulled the lower left molar forward to close all space without the need for an implant or bridgework.



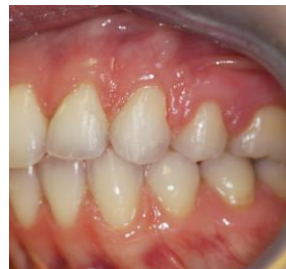# Opening space for and Closing Lateral Openbite with Implant



This young lady presented with a failed RCT on her upper left cuspid which eventually failed and the tooth was lost. Previous orthodontic efforts to bring the cuspid down also caused the adjacent teeth to intrude.



Here we can see an implant has been placed with a temporary crown (you Cannot see the crown in the X-Ray) with braces to use the implant as As anchorage to pull the adjacent teeth down into contact.

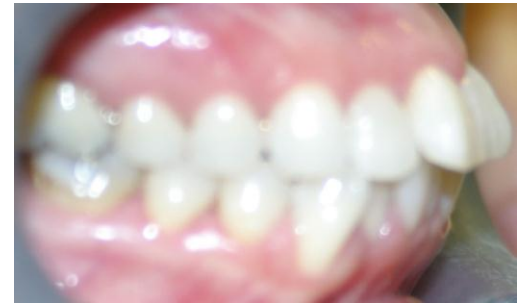
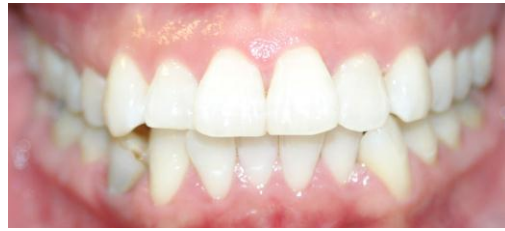
Now after braces and after the final implant crown has been placed allowing The gums to heal; note the solid contact between upper and lower teeth. The Entire process was 8mo.

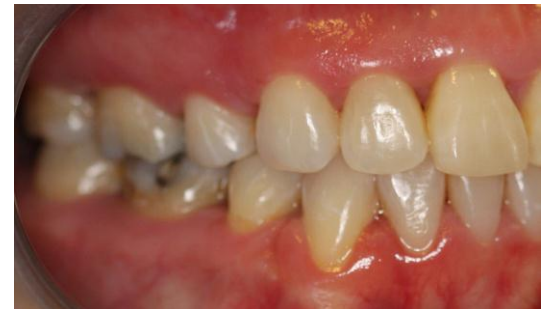
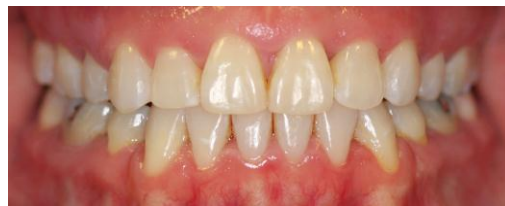
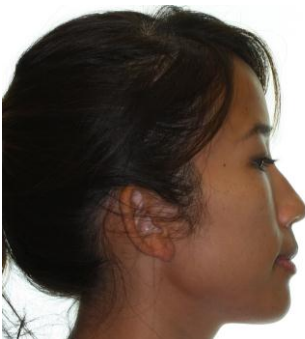

## Adult Class I Protrusion, 4 Bicuspid Extraction and Braces

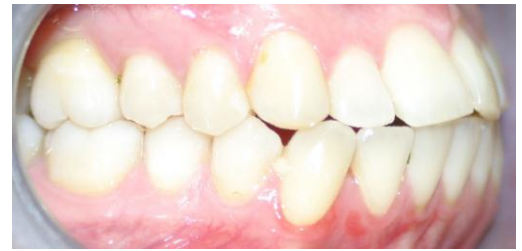
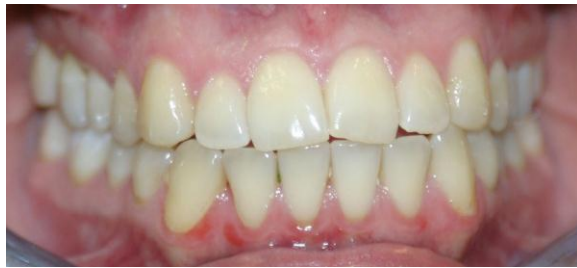
**This adult presented with protrusive and rotated front teeth and crowding in her lower arch. Additionally, she was beginning to develop recession from the thin gingival due to front teeth leaning out so far. Note the strain on lips to keep them closed in rest position.**

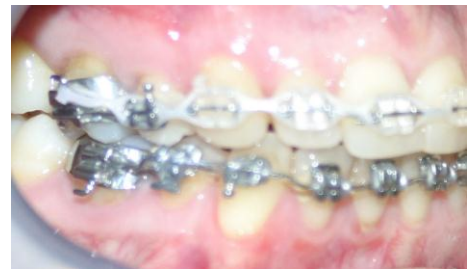
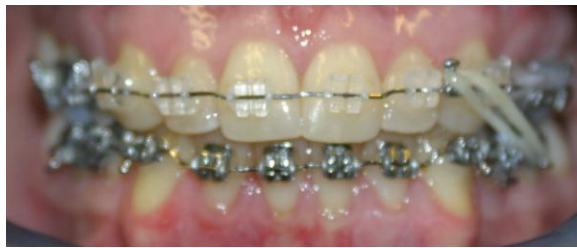
**Following braces with removal of all four 1<sup>st</sup> bicuspid, we retracted or pulled back her front teeth over the supporting bone to reduce protrusion and improve overall function; of course all alignment was corrected as well. Note the more relaxed lip posture at rest following extraction therapy.**

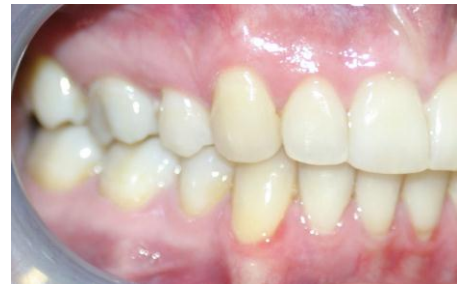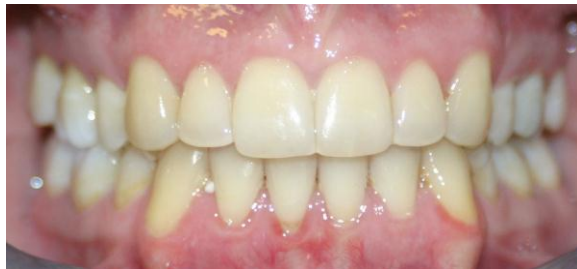# Adult with Protrusive teeth and Mild Openbite (Previous relapse from non-extraction braces)



**Initial Photos show the teeth pushed outward opening the front bite; previous braces aligned teeth but at the expense of over-expanding the teeth, pushing them out of the bone.**

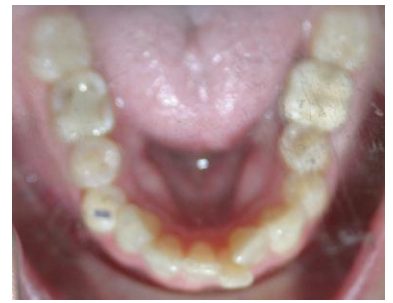
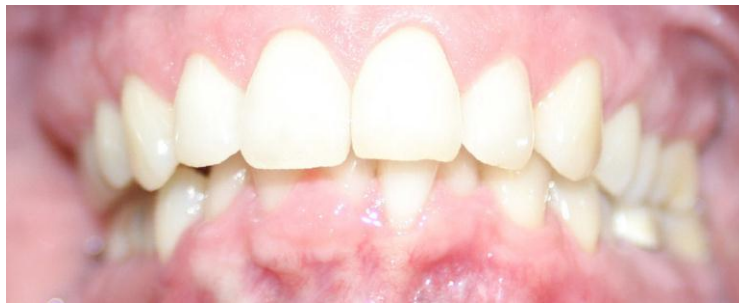
**After 18 months of braces, all four 1<sup>st</sup> bicusps were removed and the spaces closed by pulling the front teeth back into the bone. Note how the bite closes naturally.**

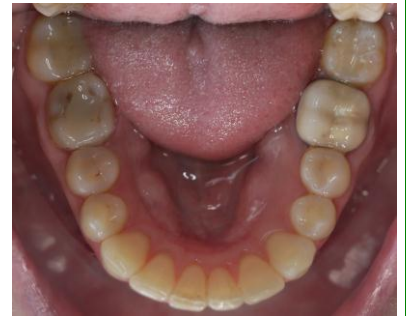
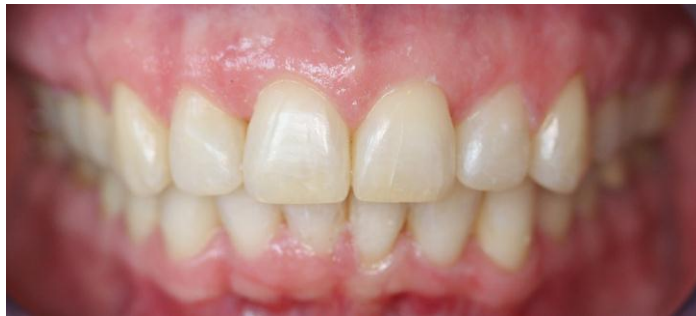
**12 months into retention (after braces) you can see ideal overjet and overbite have been restored and all space for the removal of the four teeth has remained closed.**

## Adult Crowding, Traditional Braces



**This 46 year old patient presented with a deep bite, severe crowding in her lower arch and a 3mm midline discrepancy. Full braces were planned.**



**Now at 48 years old, we have aligned the teeth, opened her bite to expose her lower teeth and corrected her midlines. Note the ideal fit of teeth achieved without removal of any teeth.**

Member  
American Association of  
Orthodontists

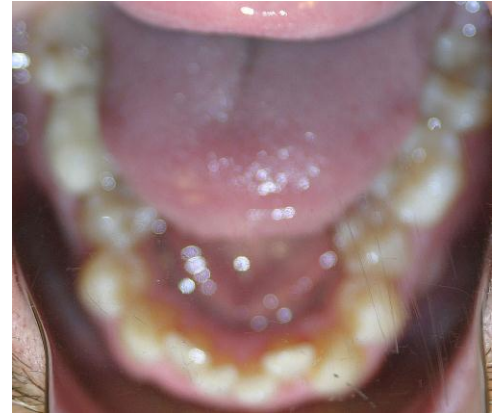
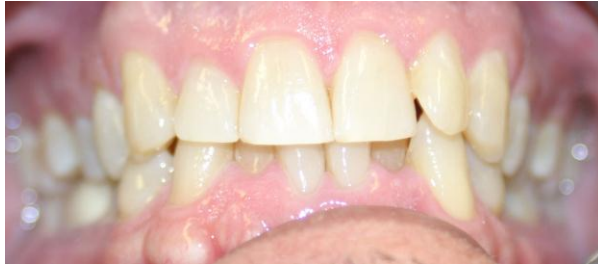
[www.BracesAustin.com](http://www.BracesAustin.com)

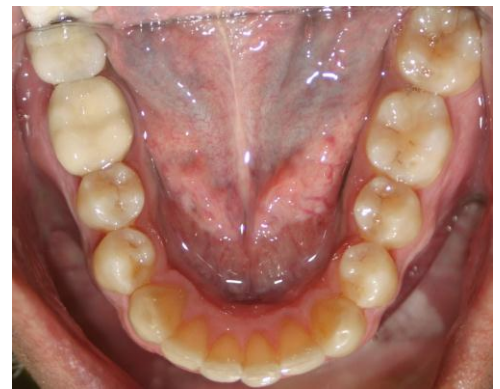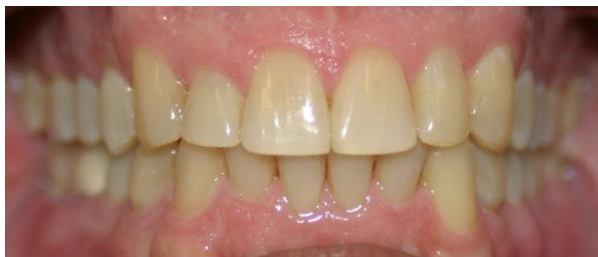 **DIPLOMATE  
AMERICAN BOARD  
OF ORTHODONTICS**



## Adult Crowding treated w/ Braces 18mo, non-extraction



**This patient presented with severe crowding of his lower teeth from years of constriction from the upper arch form. Note the upper back teeth are pushed in creating a shadow.**



**Following 18 months of braces, we have rounded out the upper arch which then gave us room to align the lower teeth. A small amount of reshaping was performed between the lower teeth to gain enough room for all of the teeth.**

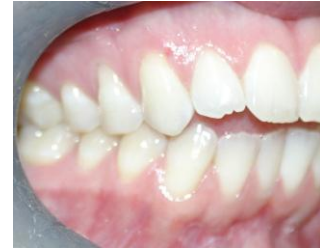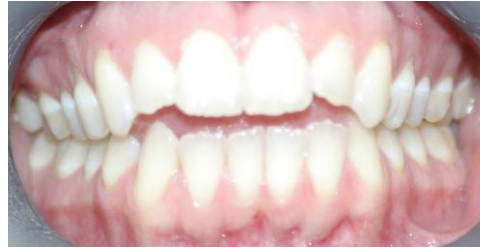Member  
American Association of  
Orthodontists



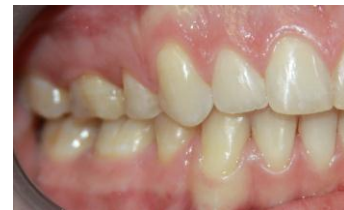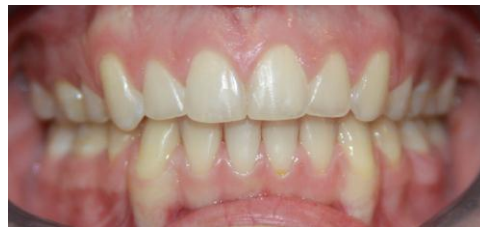[www.BracesAustin.com](http://www.BracesAustin.com)

 **DIPLOMATE  
AMERICAN BOARD  
OF ORTHODONTICS**

# Adult Openbite with Dental Protrusion, Treated with Braces and Extraction of 4 bicuspids



Initial Photos taken at age **21y 5mo** showing an anterior openbite, crowding, rotations and protrusive front teeth. Braces were planned along with removal of four bicuspids.

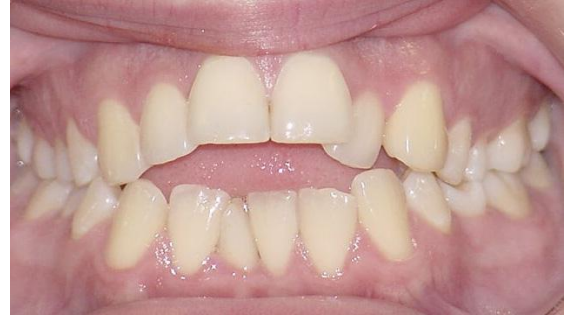

Photos taken at **23y 9mo**, a full 6mo following removal of braces, show the bite corrected and remaining closed with all spaces closed following removal of bicuspids. Note the newly corrected inclination of teeth in profile with reduced protrusion and a solid Class I occlusion.

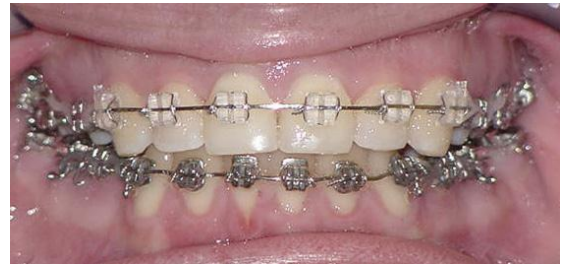## Anterior Open Bite Corrected With Braces Alone



29 year female will no habits predisposing the openbite. Note the severely rotated lower incisor and the degree of severity of her open bite. Treatment recommended was extraction of all 1<sup>st</sup> bicuspid and retraction of front teeth to close the bite.

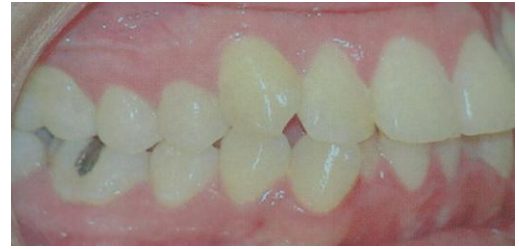
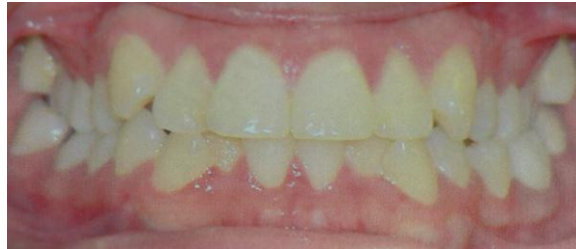
At 23 months, the bite is closed and all space from the removal of bicuspid is now closed. There is a small gingival defect from the correction of the lower incisor rotation.

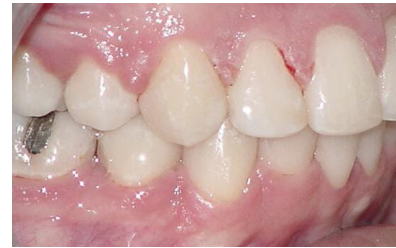
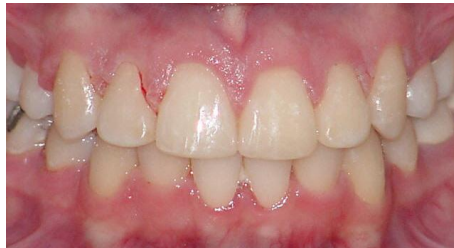


## Adult Class I Crowding, 4-bicuspid extraction (5 years post-orthodontics showing stability)



**20y 0mo** Initial photos showing severe crowding with poor occlusion; note the tip to tip contact at the cuspids and the “flaring out” of upper incisors.



**28y 8mo** Pictures taken 5 years after the removal of braces (which included removal of all 1<sup>st</sup> bicuspid). Spaces remain closed from the teeth removed and the alignment has remained stable; compare now the side occlusion or fit of the teeth as well as the new uprighted position of upper incisors.



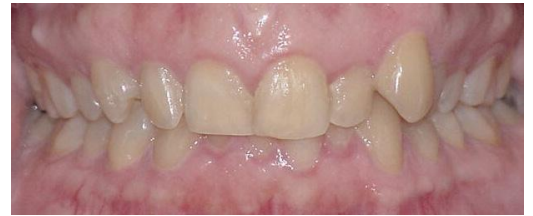[www.BracesAustin.com](http://www.BracesAustin.com)



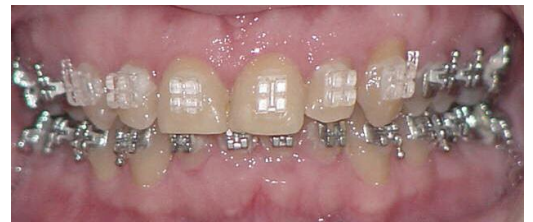# Adult Missing Upper Cuspid, Midlines Shifted



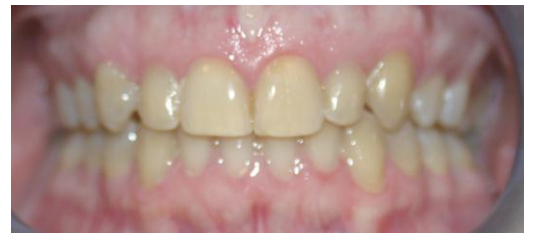**33y 1mo** Initial photos show the patient is missing her upper right canine and all other teeth have shifted to that side. Additionally, she has severe crowding with a deepbite.



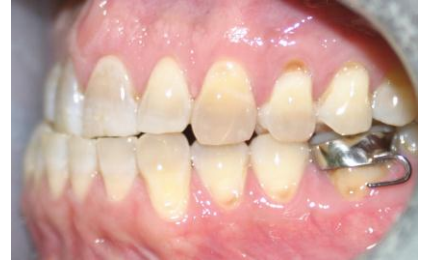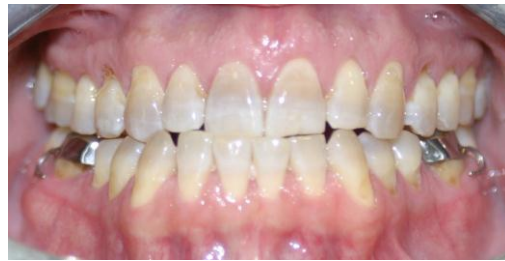**34y 2mo** 12mo into braces and basic alignment is complete. Patient was sent to remove her upper left 1<sup>st</sup> bicuspid to allow us to shift the midline back to her center, space was closed around the missing upper right canine.



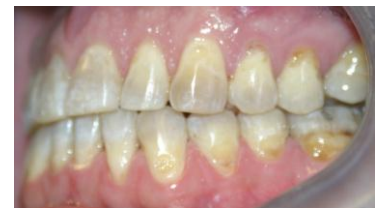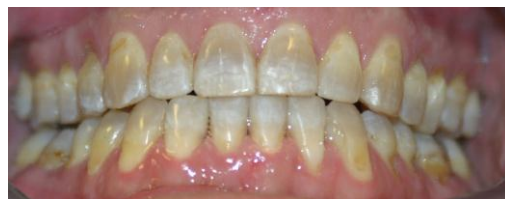**38y 7mo** A full 3 years after braces were removed, you can see the midlines have been corrected and held while the upper right bicuspid was re-shaped to better match the canine it is replacing. All space from the missing UL bicuspid remains closed.



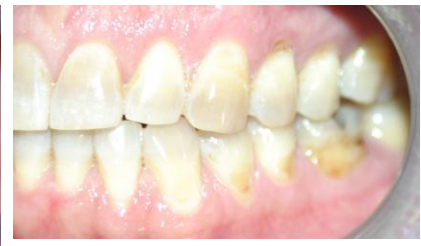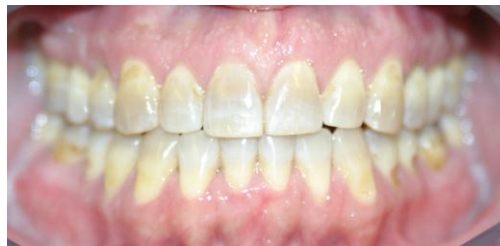## Adult Class III Underbite corrected with Interproximal Reduction (non-extraction, non-surgical)



**44y 5mo** Initial Photos showing Class III Underbite (along with evidence of previous failed efforts to correct or control the underbite)



**46y 5mo** Immediately following correction from full braces, interproximal reduction was performed on lower bicuspid and cuspids one at a time as we pulled each lower tooth back under the front teeth.



**47y 9mo** Now at 18mo into retention (after braces), the teeth have settled into a tight occlusion while maintaining the ideal overjet and overbite provided by the orthodontic treatment. Note the lack of any new wear on the edges.

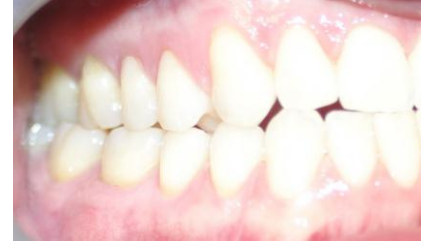
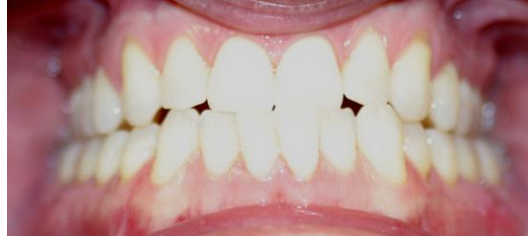
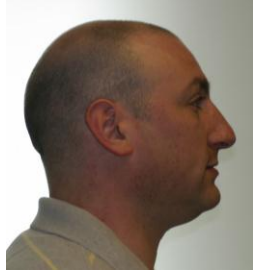[www.BracesAustin.com](http://www.BracesAustin.com)

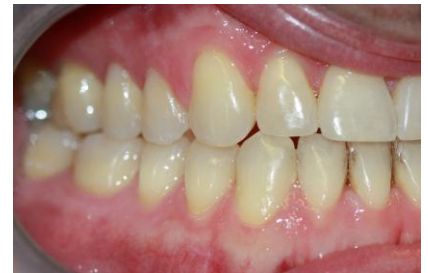
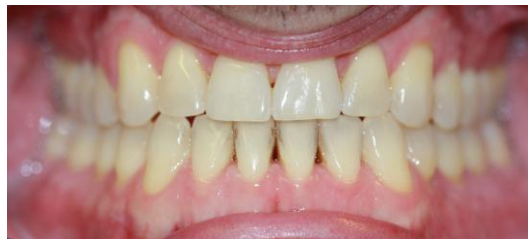


## Adult Crowding mild Class III/borderline Underbite

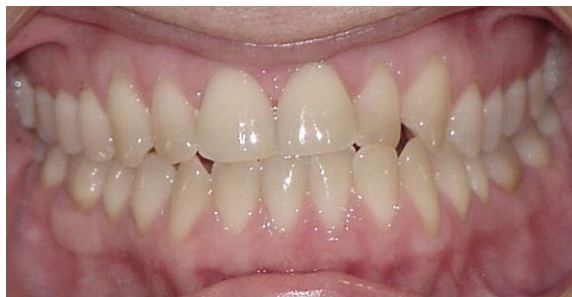

**35y 1mo** Initial photos showing a near underbite with heavy anterior occlusion and posterior crossbite; treatment was planned to place braces and reshape lower teeth to allow retraction and correction of underbite. Treatment time was 24 months.

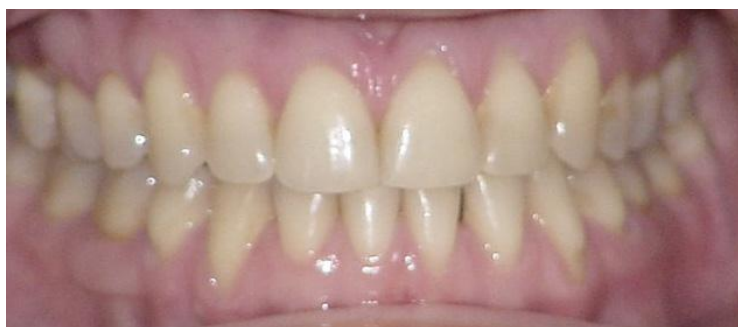

**38mo 7mo** 18mo after removal of braces. The correction of the underbite through retraction of the lower teeth has remained stable as well as the posterior crossbite correction. Although extractions could have been justified to help stability, the facial profile with insufficient lip support made extractions contraindicated.

## Adult Class III; Braces and Extraction all 1st Bicuspid

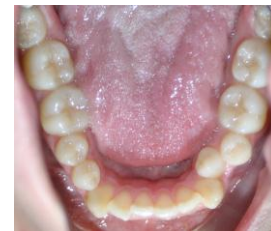
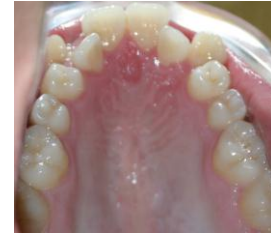
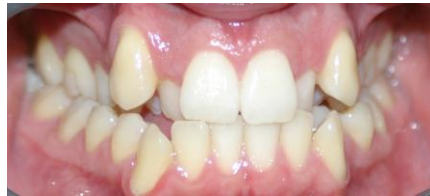**43y 1mo** Initial photos showing Class III underbite/crossbite with canted occlusal plane (high on the patient's left side).

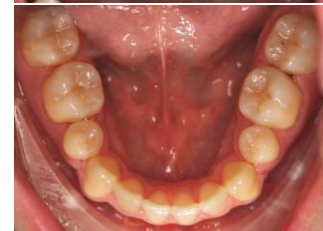
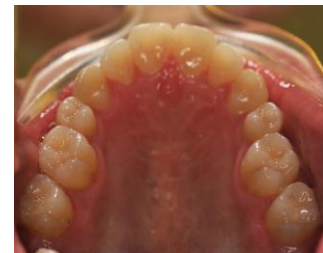
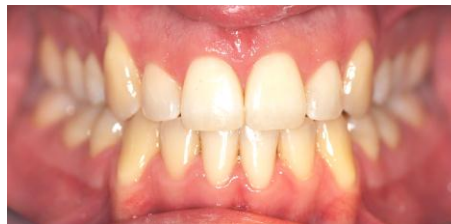**48y 1mo** Photos taken *3 years after orthodontic treatment* which involved removal of 1<sup>st</sup> bicuspid and retraction of lower teeth behind her upper teeth. The occlusal plane was leveled in the process and overjet was restored to ideal. Note the stability of the correction.

# Adult Class III Underbite with Severe Crowding & Bilateral Posterior Crossbite, 4 bicuspid extractions



Initial Photos, age 25y 8mo patient with a partial underbite, severe crowding, and anterior/posterior crossbite.



Final photos taken 6mo following removal of braces; Alignment has been corrected along with the underbite and crossbites through extraction of 1<sup>st</sup> bicuspid and differential space closure.



[www.BracesAustin.com](http://www.BracesAustin.com)

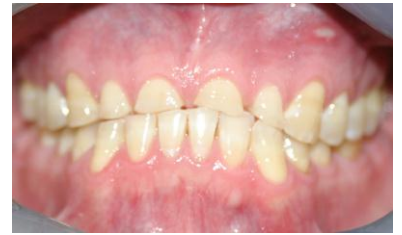
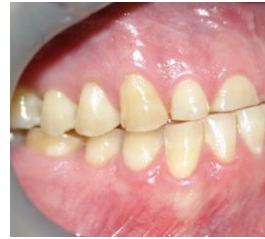


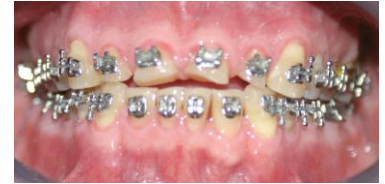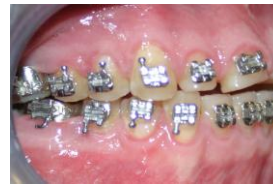# Adult with Severe Wear; Braces and Full Restoration



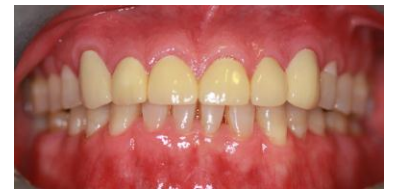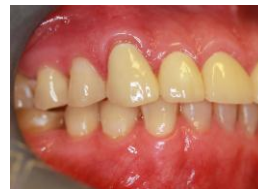At 47 years old, this patient has worn down all of his front teeth due to a poor occlusion. Note that once the lower teeth ground through the enamel of the uppers, the wear became much more severe to point of grinding into the gum tissue. Also note the upper teeth actually rest behind the lower teeth.



14 months into full braces, we have now “leveled” the lower incisors and pushed up the upper incisors. Lower incisors were retract or pulled back allowing space for restorations/veneers to be placed to restore the worn edges of the upper teeth while regaining overjet previously lost.



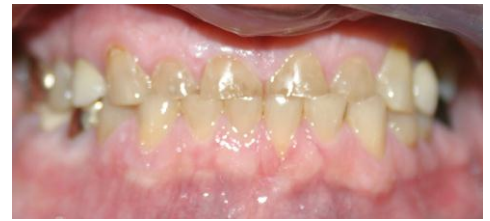After 18mo of braces and full veneers on upper anterior teeth, function and esthetics have been restored to ideal overjet, overbite and alignment; none of which could have been corrected without both braces and veneers.



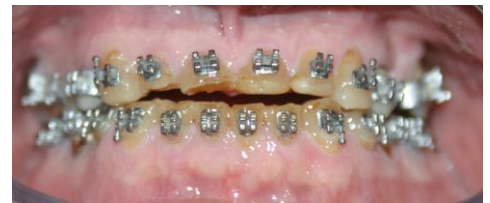# Adult with Severe Wear, Reduced Vertical Facial Height



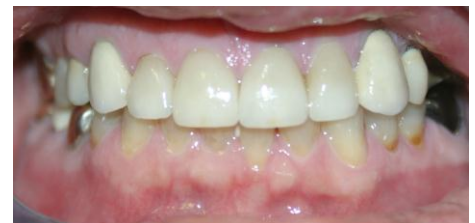**58y 10mo** patient presents with severe long-term wear, through his enamel, due to lingual tipped upper incisors and a lifetime of functioning on his front teeth. Note the “scrunched” face from a persistently decreasing vertical facial height.



**60y 0mo** Braces were used to re-open his bite, increase lower facial height and provide space for restorations. The upper incisors were also uprighted to their correct angle (v. leaning backward into the bite)



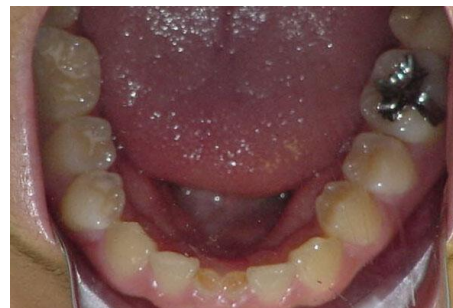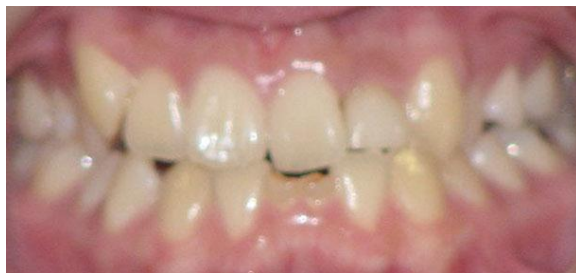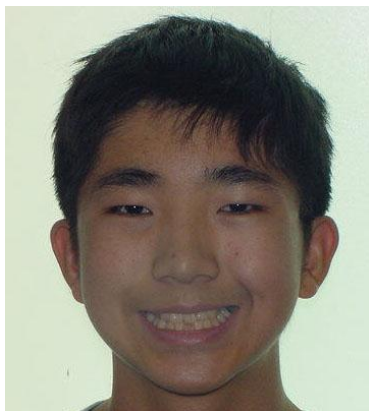**60y 5mo** Braces have been removed and restorations placed by his general dentist. Occlusion is now restored with improved esthetics however the greater change is in the increase facial height (compare the pictures on the left).



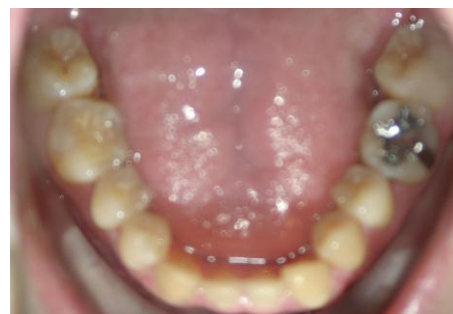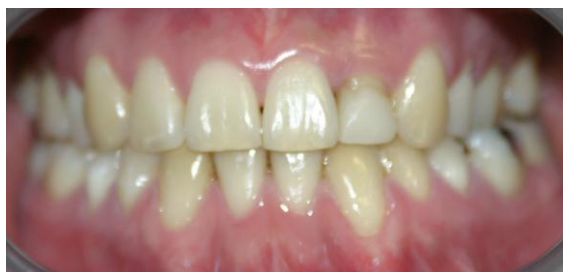[www.BracesAustin.com](http://www.BracesAustin.com)



## **Braces with Extraction of upper 1<sup>st</sup> bicuspid to balance missing lower central incisors**



**This young man presented with congenitally missing lower central incisors (note the retained baby teeth still present in the lower arch) and severe crowding. Treatment was planned with full braces including removal of the baby teeth along with a single 1<sup>st</sup> bicuspid on each side in the upper arch.**



**Now one year out of braces, upper teeth have been aligned and all space closed from both upper 1<sup>st</sup> bicuspid and the missing lower incisors. Note that his midlines have also been corrected.**

Member  
American Association of  
Orthodontists

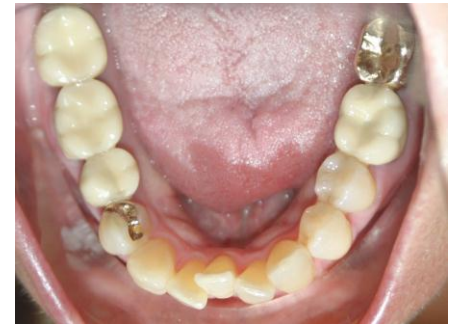
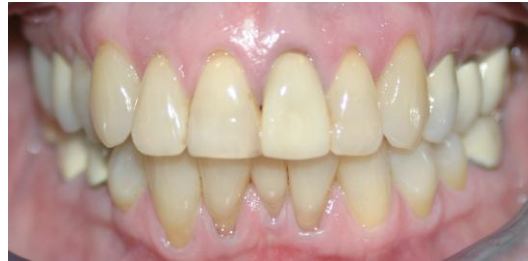
[www.BracesAustin.com](http://www.BracesAustin.com)

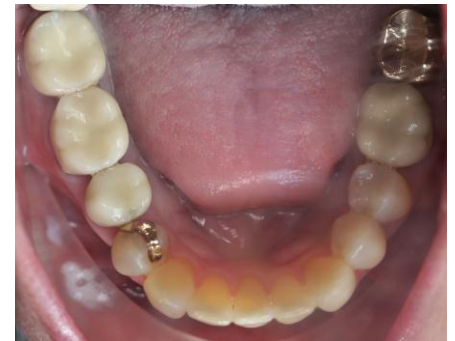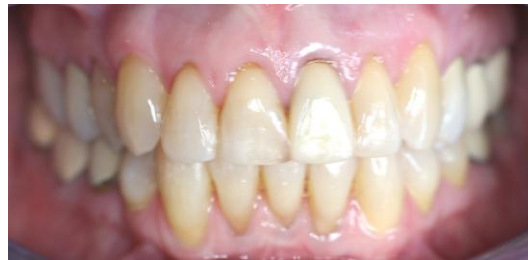 **DIPLOMATE  
AMERICAN BOARD  
OF ORTHODONTICS**



# Adult Crowding Single Arch Treatment (lower arch)

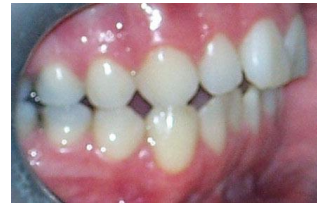
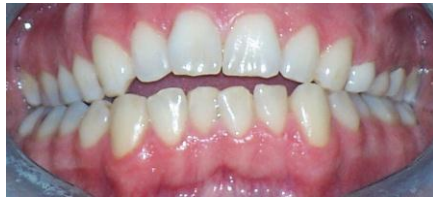
**At 70y 7mo, this patient wanted to correct the crowding she had in her lower incisors because they were difficult to clean and were losing bone. Note that a single incisor had been taken out years ago in previous orthodontic treatment but the teeth relapsed. Braces were planned for the lower arch alone.**

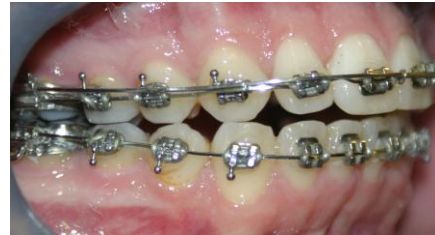
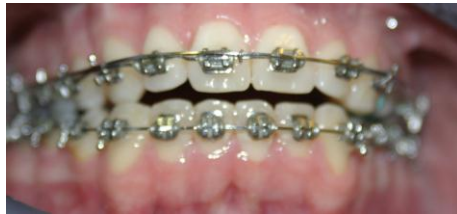
**Now at 71y 10mo, braces have been removed and the alignment restored following interproximal reduction of lower bicuspid to allow some retraction of the front teeth (and avoid the typical but unstable dental expansion). By pulling the lower teeth back during alignment, we have also reduced the risk of more extensive gum recession.**

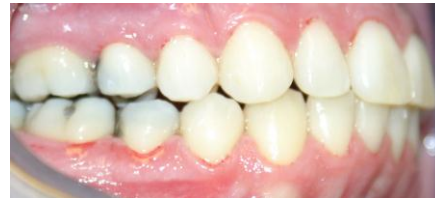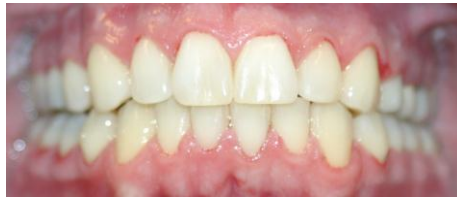# Adult Openbite with Canted Occlusion



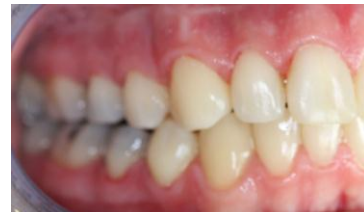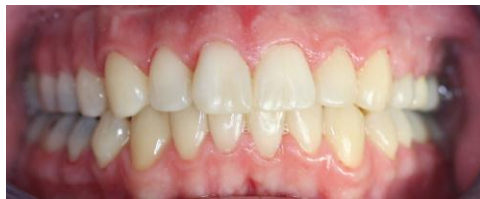**Initial photos showing openbite and canted occlusal plane with cusp to cusp side occlusion (Class II).**



**Now in full braces, we have begun leveling the arches and setting up to shift the jaw forward.**



**At the time of removal, alignment is complete and the anterior openbite has been closed leaving the patient in heavy anterior occlusion (assuming we will have some relapse over the retention term).**



**Now 12 months after braces, the front teeth have relapsed as planned allowing full occlusion. Note the new canine position cusp tip to groove (Class I).**

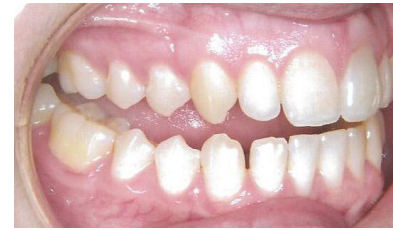
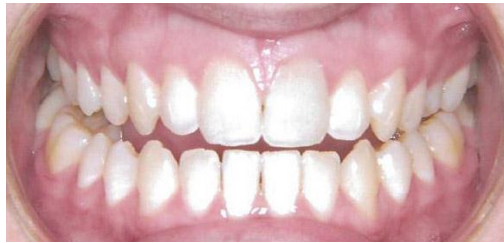
[www.BracesAustin.com](http://www.BracesAustin.com)

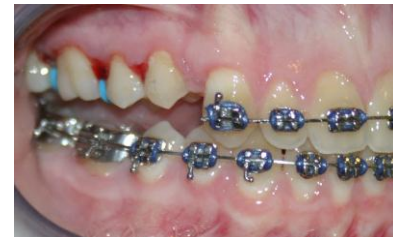
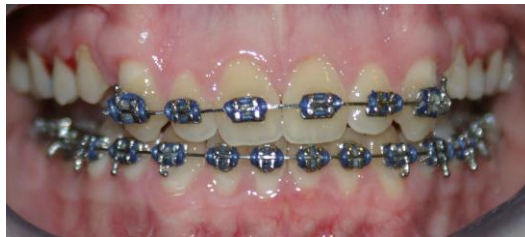


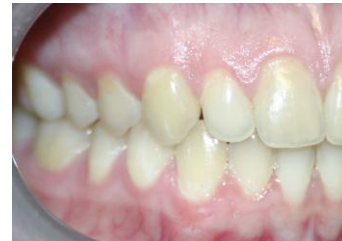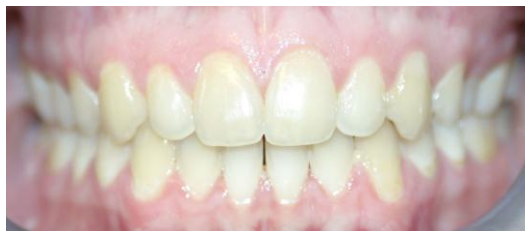# Openbite closed through posterior intrusion (RPE with fixed overlay) and full braces



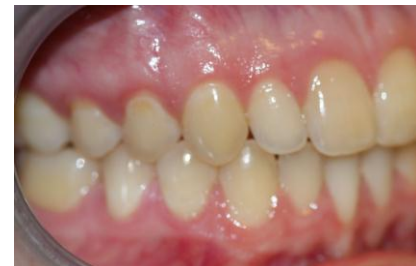
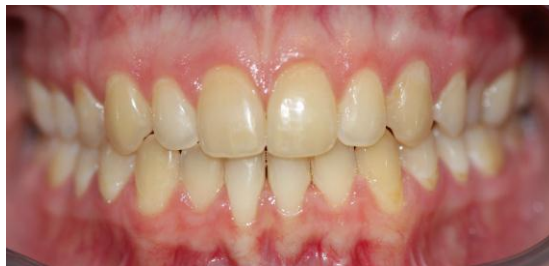**This patient presented with a severe openbite with contact on only a few molars and a bilateral posterior crossbite (note the lower teeth are wider than upper teeth).**



**A bonded RPE with overlay was placed and held for 4 months to intrude upper posterior teeth; upon removal, the overjet was instantly over-corrected.**



**Braces were continued for another 6 months to allow the back teeth to settle and to finish arch coordination with the newly closed bite.**

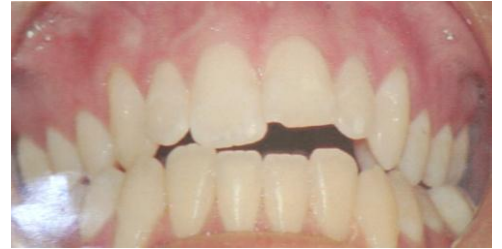


**One year following removal of braces and the bite remains solidly closed.**

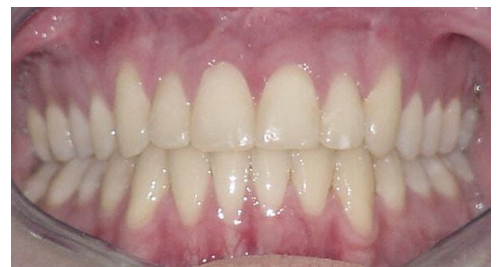

## Adult Openbite closed through Maxillary (upper jaw) Surgery and Full Braces

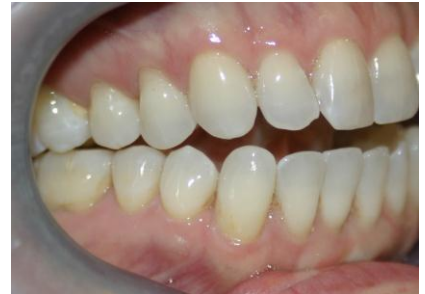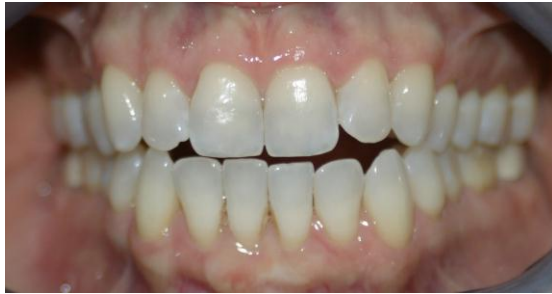This 18y 7mo adult presented after two previous failed attempts to close his openbite with braces. Note the narrow upper jaw and the “canted” smile line.



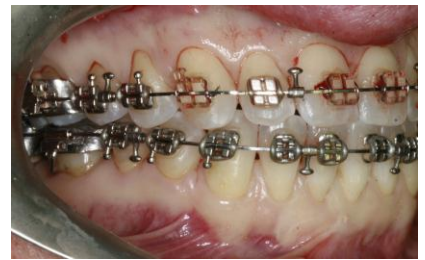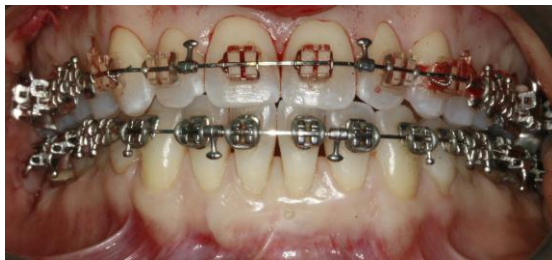Now following braces and surgery which were used to expand his upper jaw and push the back portion of his upper jaw upward allowing the front portion of the upper jaw to come down and close the bite. Braces were used for @12months prior to the surgery then left on to help stabilize the jaws during surgery. Final adjustments were then made and braces removed. Time in treatment was @20 months. *Pictures were taken 12 months after removal of braces to show stability.*



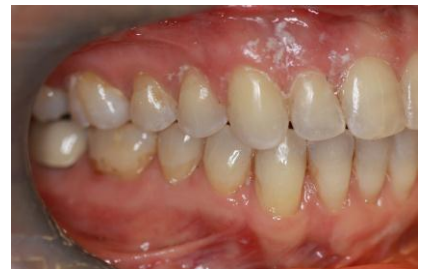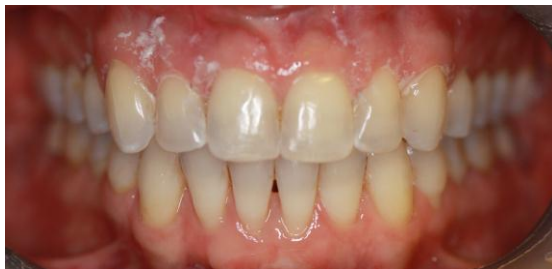# Adult Openbite Corrected with Braces and Surgery



**36y 1mo** Initial Photos showing Anterior Openbite with mild crowding. Braces were planned to align teeth along with surgical assistance to impact the posterior maxilla.

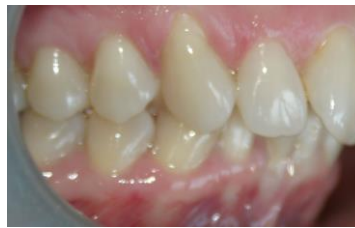
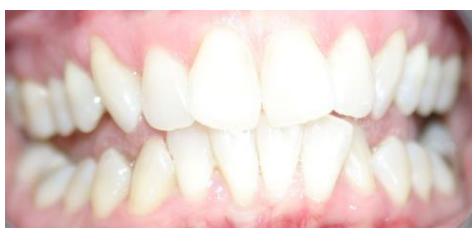
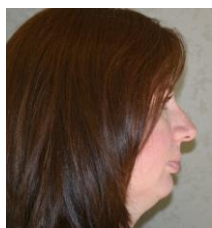**36y 11mo** Patient has been in braces 10months and was sent to an oral surgeon for her posterior impaction surgery; photos were taken immediately following surgery.



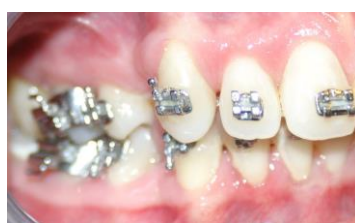
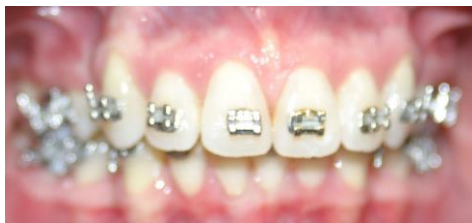**37y 4mo** After only 13months, the day of removal; Note the tight occlusion from incisors to molars.

## Adult Class II Mandibular Hypoplasia with Maxillary Dental Protrusion; Extraction Therapy and BSSO Surgical Advancement of Mandible



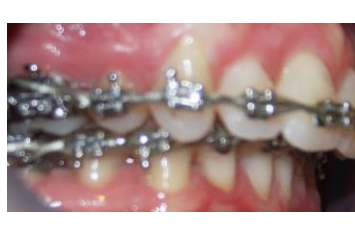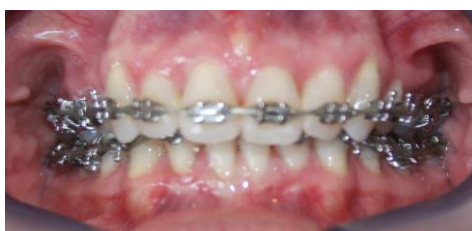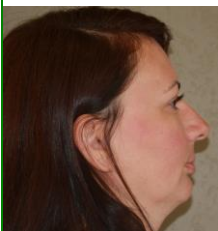**40y1mo**

Severe Crowding  
Severe Deepbite  
10mm Overjet  
Retruded Mandible



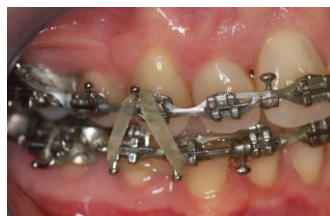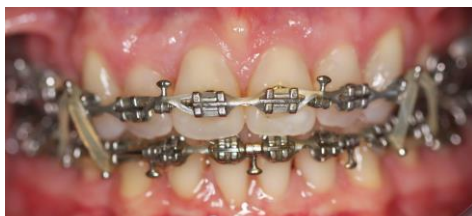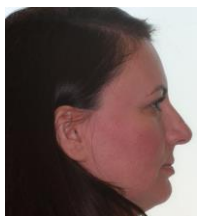**41y 6mo**

All 1<sup>st</sup> bi's removed  
Bite opened/leveled  
Ext. spaces closing  
Waiting on Insurance



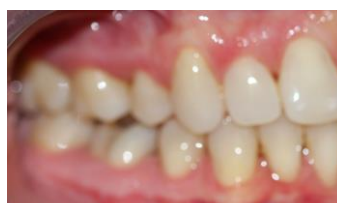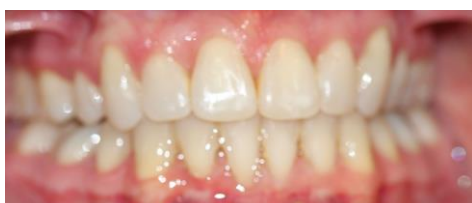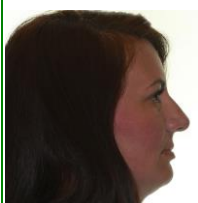
**42y 11mo**

Spaces all closed  
Lower teeth retracted  
to max. advancement  
Waiting on Insurance



**43y 6mo**

2 weeks post-surgery  
Overjet Corrected  
Overbite Ideal

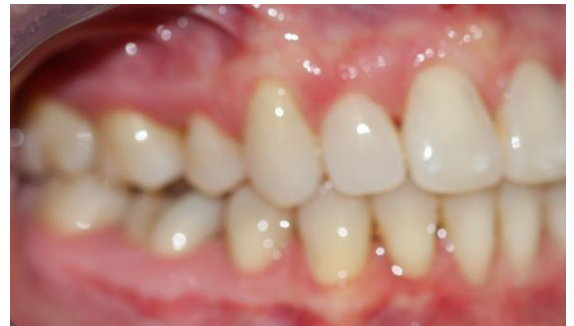
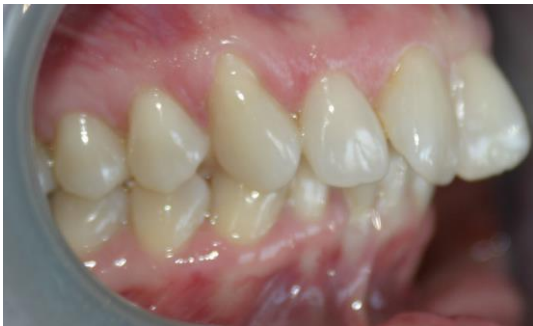
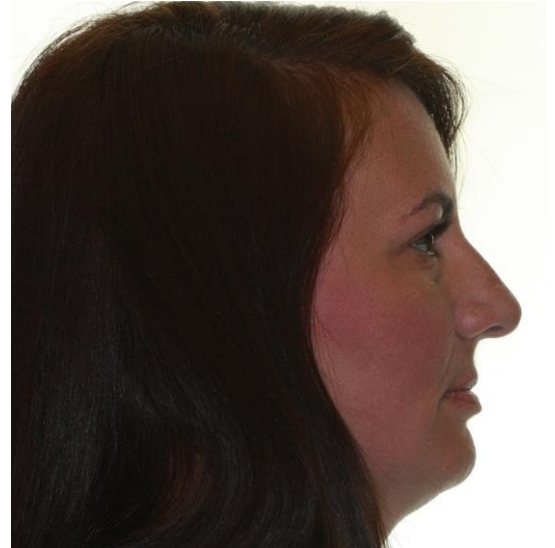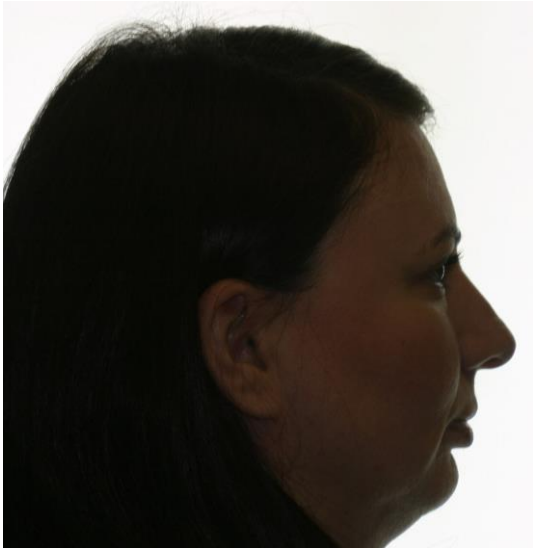**43y 9mo**

Day of removal  
All space closed  
Class I ideal OJ/OB  
Great profile



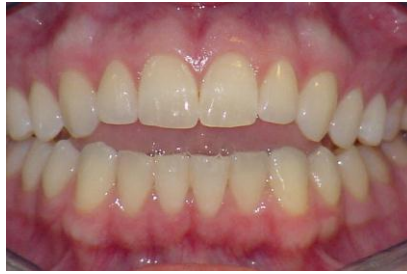## Surgical Mandibular Advancement Profile (Before/After)



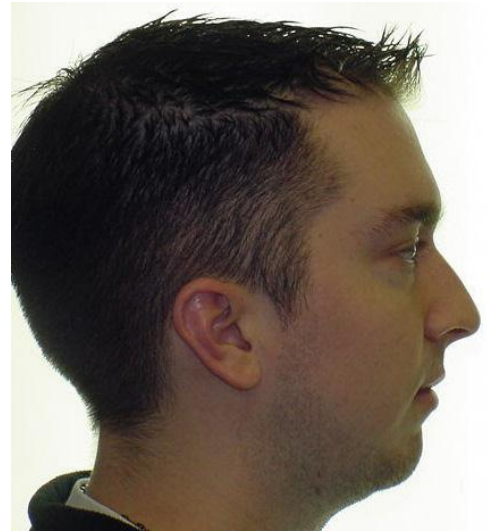This 40 year old patient presented with a full-step Class II malocclusion and severe mandibular retrusion. Crowding was severe and her lower incisors occluded into the roof of her mouth. Note the facial profile and 10mm overjet.

Now at 43, following removal of all 1<sup>st</sup> bicusps, space closure and surgical advancement of her lower jaw. Note the crisp Class I interdigitation and the newly established plane of occlusion with bite opened.

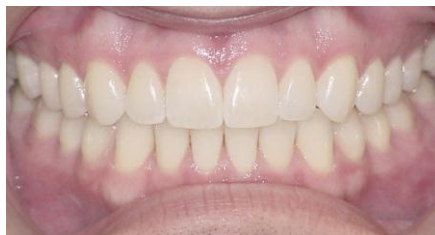## **Class II Severe Openbite Corrected with Braces, Lower Jaw Surgery and Chin Advancement**



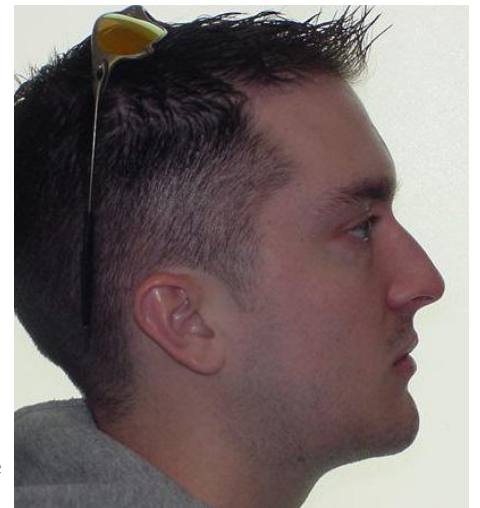**This 24 year old presented with an anterior openbite which had relapsed back open after braces were performed as a teen. Not only was it impossible for him to bring his teeth together to chew, he was unhappy with his profile.**



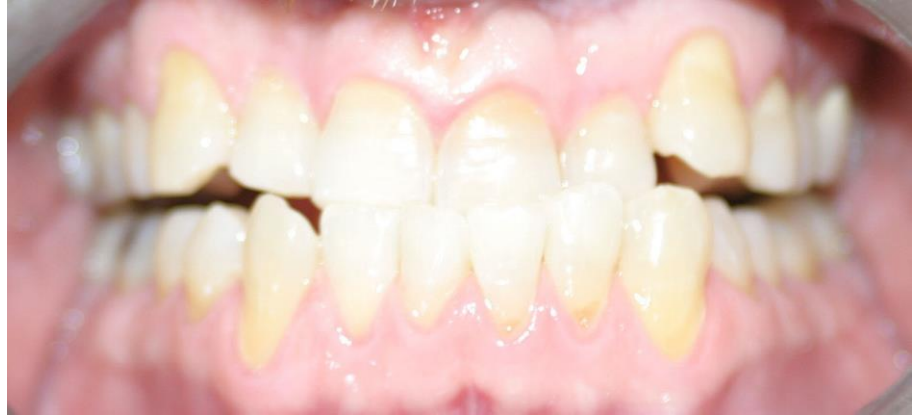**Full braces were placed and basic alignment was completed in each arch, leaving the bite open. The patient was then sent for lower jaw advancement surgery where the lower jaw was moved forward and rotated upward to close the bite. Additionally, we had the oral surgeon advance the patient's chin several millimeters to address the facial balance.**



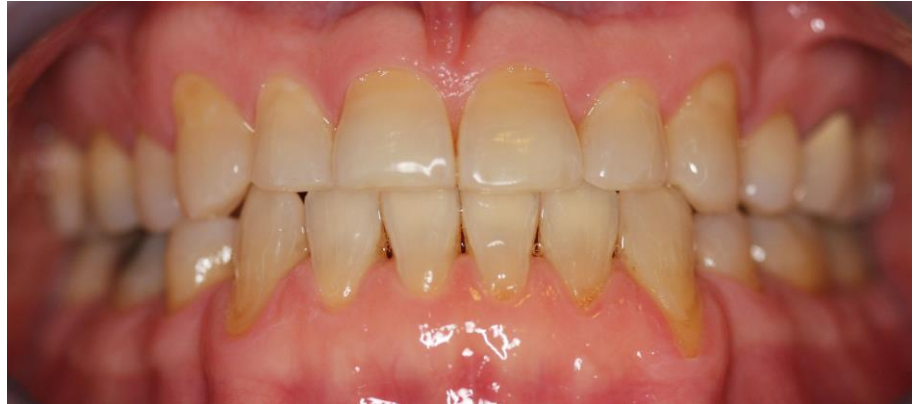**Note the bite is now closed with ideal alignment and overjet as the lower jaw was moved. The rotation of the jaw closed the bite as braces were used to re-align and re-fit the teeth into the new, corrected relationship. Note also the new profile/chin position**



## Adult Class III Underbite, Treated with 4 bicuspid Extraction and Full Braces



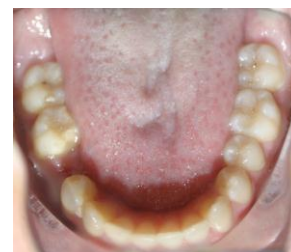
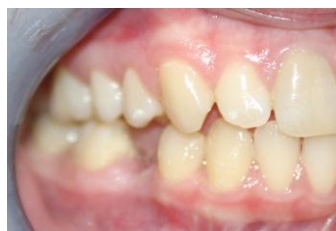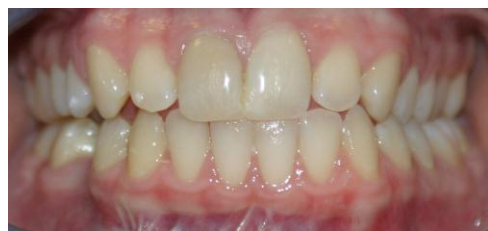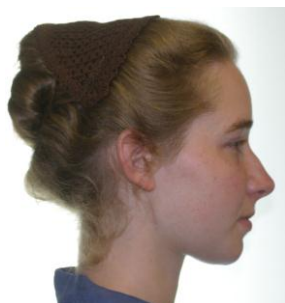**38y 9mo** Class III Underbite with Crowding and Chipped/worn teeth.



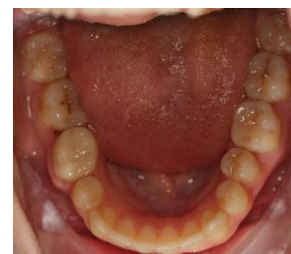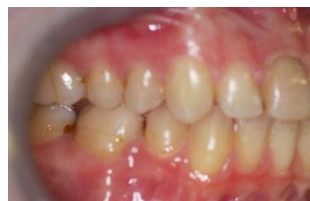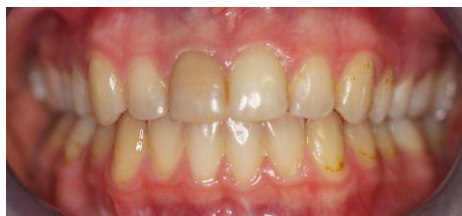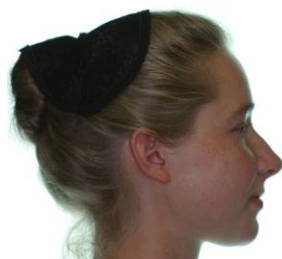**41y 0mo** Following 27 months of braces which included removal of 1<sup>st</sup> bicuspid. Note the marked improvement of overjet and the leveled arches.



# Mutilated Dentition with Poor Post-surgical Occlusion and Avulsed/Missing Lower Right Bicuspid

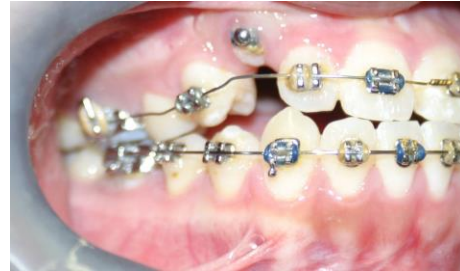
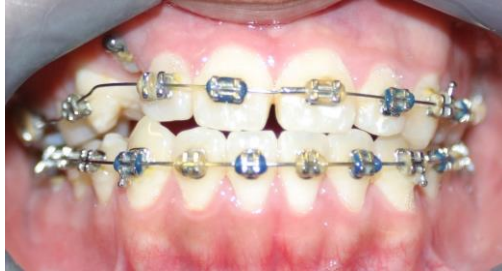
**19y 6mo** Initial visit following accident that included fractured right condyle and right body of the mandible and avulsion of tooth #29. Occlusion was set in the ER without orthodontic guidance or appliances leaving the bite open on the right side and in crossbite left side.

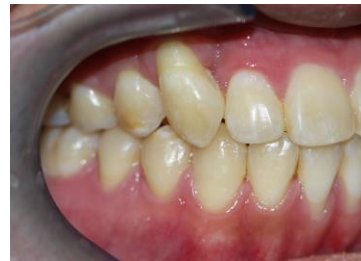
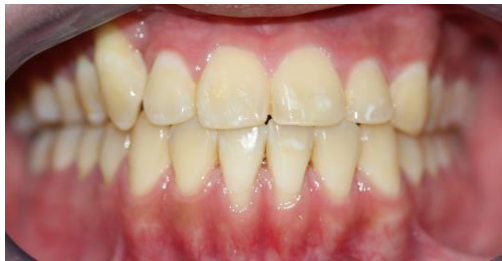
**22y 10mo** 6mo after braces were removed, note the crossbite has been corrected and the occlusion restored to ideal. Lower right molars were protracted forward to close the space from the avulsed and missing tooth #29. Note the correction of the midlines and the solid Class I cuspids despite the unilateral protraction of molars.

# Ankylosed Cuspid Extracted and Re-implanted



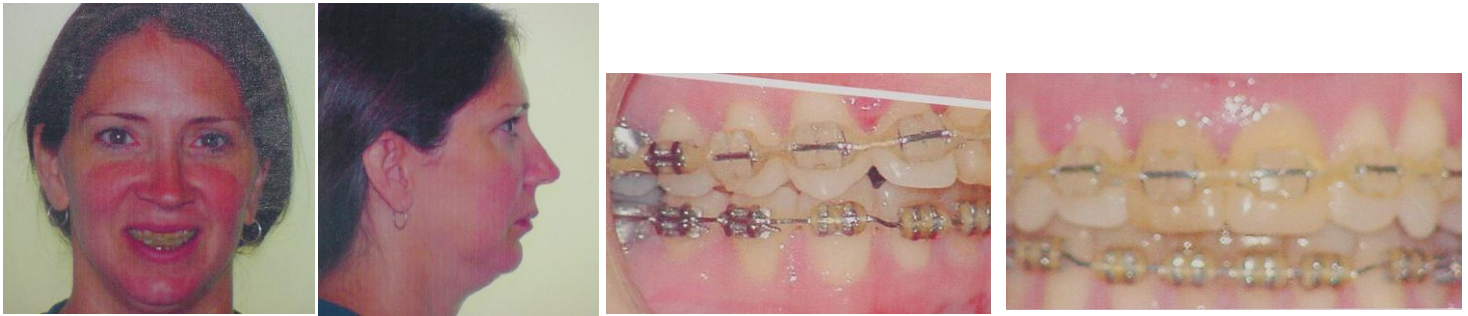This 17y 3mo patient transferred in with an impacted and exposed upper right cuspid; efforts to move had been unsuccessful for 3 years and the tooth remained solid; note the distortion in the arch as the adjacent teeth were being pulled up by the ankylosed (fused to bone) cuspid.



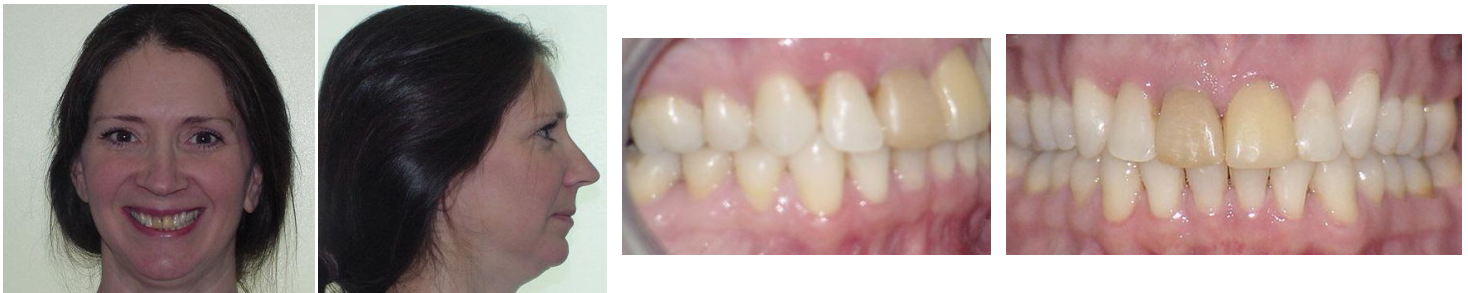The cuspid was re-exposed but again failed to move. Finally, we had the surgeon extract the cuspid and re-position it during re-implantation into the erupted position; the remaining arch was re-leveled and the re-implanted tooth re-stabilized (and likely re-ankylosed). We expect to have a connective tissue graft performed along with a root canal during the retention but the cuspid is solid and asymptomatic at age 20.



# Protrusive Upper Lip Treated with Extraction of Upper Bicuspids



This patient came to our office in full braces with a full upper lip and excessive overjet. She was told that the only option to correct her bite would be surgery. Instead, we removed a single tooth on either side of her upper arch and pulled the upper front teeth backward to meet the lower teeth (see below).



After 12 months, the two teeth have been removed and the spaces closed completely. Note the tight contact between the upper and lower teeth as well as the lack of any excessive overjet. The facial profile is now balanced and there is normal lip support. This patient has been referred for veneers on the front two teeth.

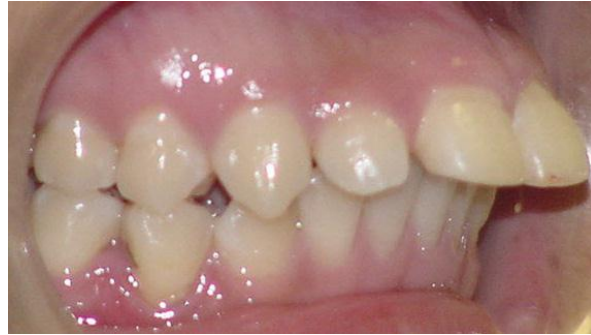
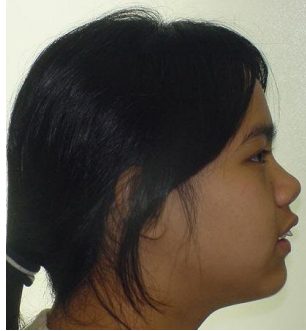
[www.BracesAustin.com](http://www.BracesAustin.com)

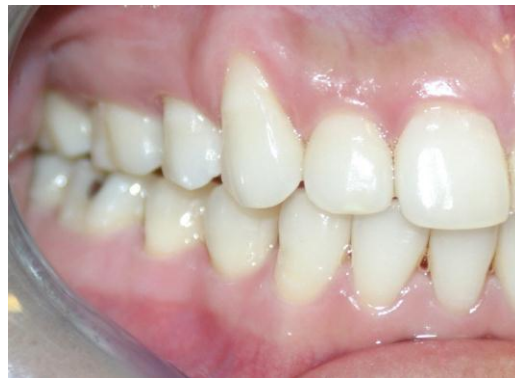



## Class II Severe Protrusion, Braces and Extraction of upper 1<sup>st</sup> bicuspid



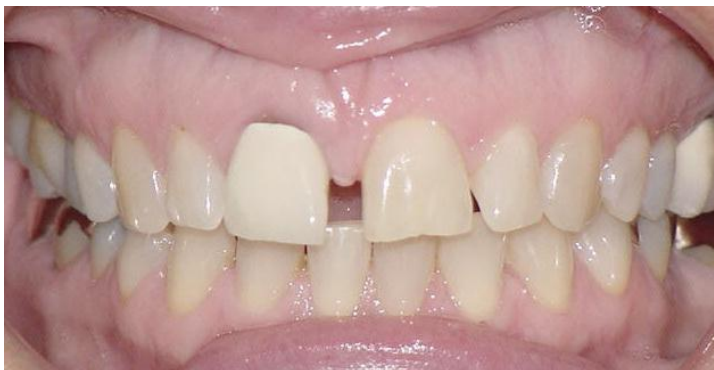**17y 6mo** Initial Photos showing severe dental protrusion with Class II end-on occlusion.



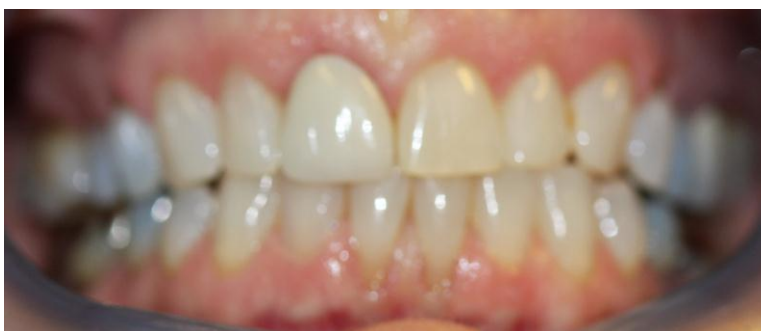**21y 5mo** A full 2 years after braces which included extraction of upper 1<sup>st</sup> bicuspid and retraction of all upper incisors back into Class I with ideal overjet and overbite; note the extraction space remains closed and occlusion has settled.



## Adult with Large Midline Diastema

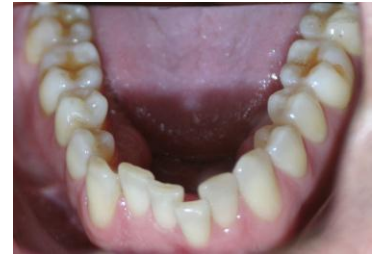
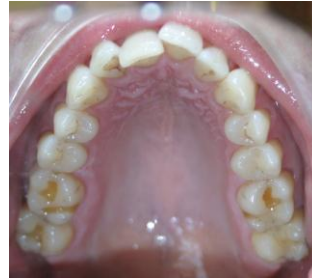
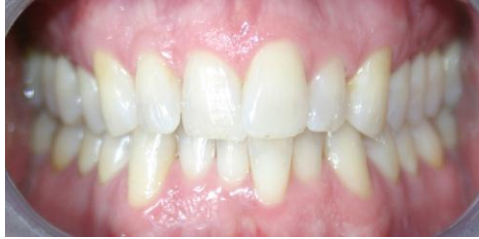This 53 year old adult presented with a large gap which has been present all of her life.

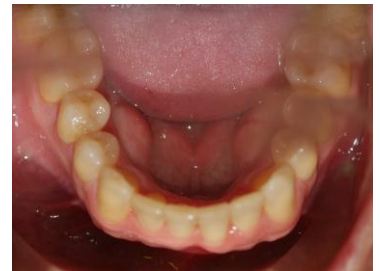
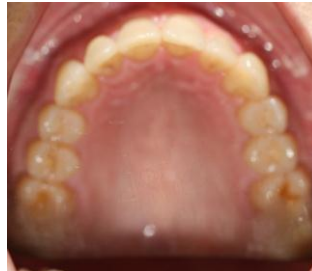
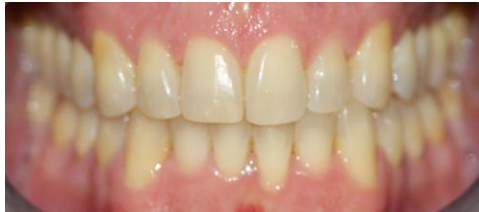Following 18mo of braces, Space was closed and the arches re-coordinated for stability. These photos were taken a full 3 years following removal of braces illustrating the stability of a properly close midline gap. The facial photos show the real story.

## Adult Crowding, Non-extraction braces



Initial photos at 41y 3mo reveal a tapered upper arch with lingually squeezed central incisor and constriction to his lower arch causing typical crowding of incisors. Braces were planned.



Photos taken 2 years after braces were removed. Patient is now past the retention period and has remained stable with good arch form and arch coordination.

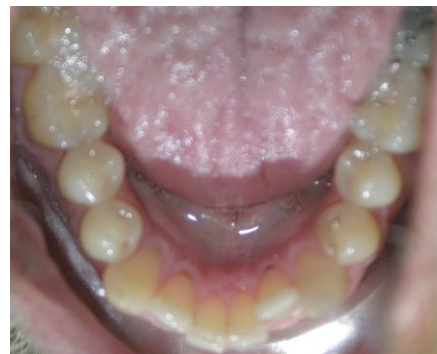
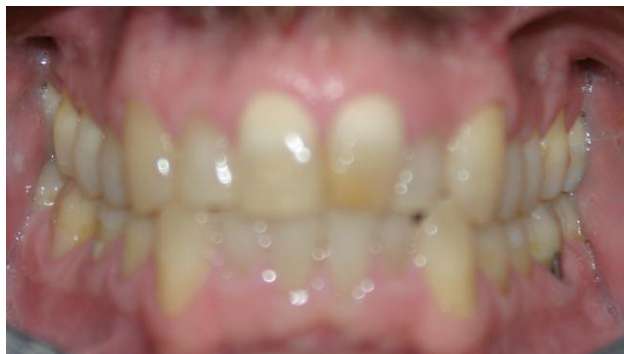
[www.BracesAustin.com](http://www.BracesAustin.com)

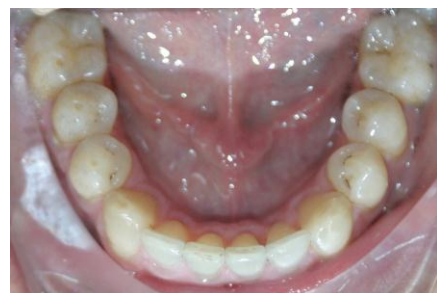
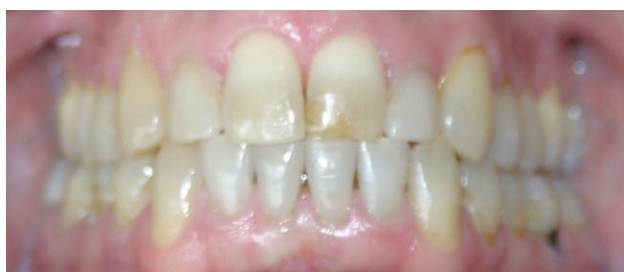


## Adult Class I Crowding, non-extraction



**46y 1mo** Initial photos showing constricted dental arches with crowding and crossbite on left canines and lateral incisor.



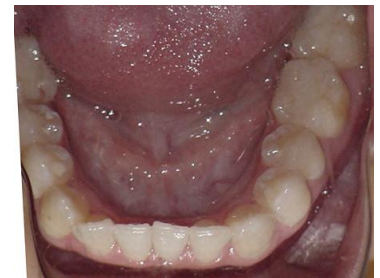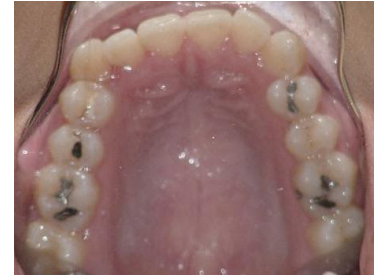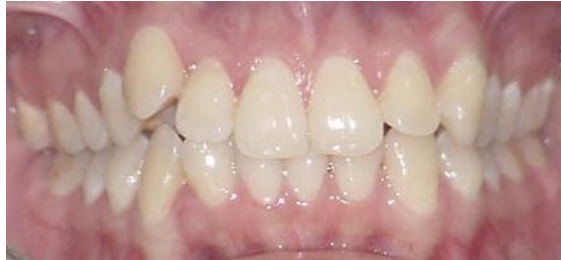**48y 0mo** Following full braces to round out his upper arch and align teeth. Lower bicuspid and cuspids were reduced interproximally to create space for retracting the lower incisors during alignment; note the improved arch form as the lower canines were pulled back into a wider portion of the arch.



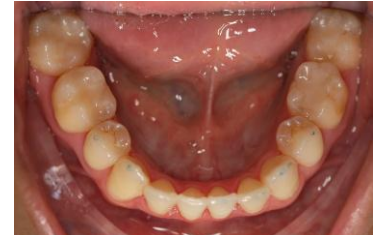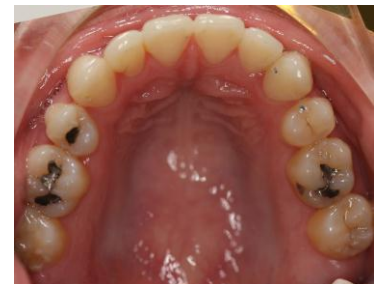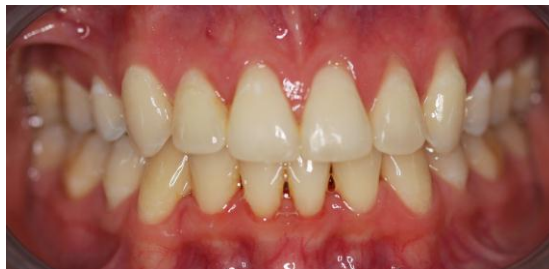[www.BracesAustin.com](http://www.BracesAustin.com)



# Adult Class I Severe Crowding, 4-bicuspid Extraction



**Initial photos 20y 0mo revealing severe crowding with no room for all of the teeth and irregular arch forms, including a narrow upper arch.**



**Photos taken 3 years following removal of braces show the stable space closure where the 4 bicuspids were removed illustrating how an ideal arch form with good alignment is more stable than severely crowded or protruded teeth without extractions; even with removal of teeth, note the full smile with no “shadowing” down the sides (buccal corridors).**



[www.BracesAustin.com](http://www.BracesAustin.com)

